

Deep Brain Stimulation Electrode Used for Radiofrequency Lesion of the Globus Pallidus Internus in Dystonia

Carlo Marras^a Giovanna Zorzi^b Cristina Lenardi^c Michele Rizzi^a
Giuseppe Messina^a Ridvan Alimehmeti^d Nardo Nardocci^b Angelo Franzini^a

Departments of ^aNeurosurgery and ^bChild Neurology, Fondazione Istituto Neurologico Carlo Besta, and ^cDepartment of Physics, University of Milan, Milan, Italy, and ^dService of Neurosurgery, University of Tirana, Tirana, Albania

Key Words

Dystonia · Radiofrequency lesioning · Deep brain stimulation · Staged lesioning · Scanning electron microscopy

Abstract

Background: There have recently been increasing case reports in the literature of deep brain stimulation (DBS) electrodes used for lesioning with satisfactory clinical success in the treatment of Parkinson disease and tremor. **Methods:** After preliminary experiments of radiofrequency (RF) lesioning with a quadripolar DBS lead, a paediatric case of generalized primary dystonia was treated by RF lesioning of the globus pallidus internus (Gpi) with an electrode previously used for chronic stimulation. In order to study electrode damage related to the RF procedure, an electron microscopy study (SEM) at different magnifications ($\times 40$ and $\times 300$) was performed. **Results:** Nine months after the unilateral pallidotomy, the patient had a good and stable control of dystonia. The MR study showed a T₁-weighted hyperintensity signal corresponding to the electrode contacts used for lesions. The SEM scans of the DBS electrode used for RF lesioning did not show alterations of the ultrastructure. **Conclusions:** The RF lesioning technique by a DBS electrode allows small and

staged lesions and could also be performed in a bilateral target. The versatility, efficacy, safety and low cost of the device make this approach suitable in selected cases.

Copyright © 2009 S. Karger AG, Basel

Introduction

Dystonia is a clinical syndrome characterized by involuntary sustained patterned and often repetitive contractions of opposing muscles that cause twisting or spasmodic movements or abnormal postures [1, 2]. The pharmacological armoury for dystonia includes anticholinergics, dopamine agonists, dopamine antagonists and benzodiazepines, often administered in combination and usually with limited efficacy [3]. Deep brain stimulation (DBS) is a reversible procedure, and the electrical parameters are adaptable according to the patients. DBS of the globus pallidus internus (Gpi) has been used for treatment of dystonia with good and stable results [4–8]. However, DBS carries hardware-related complications [9], including skin erosion or hardware infection that are often resolved by the removal of the DBS electrode and with the consequent onset of dystonic symptoms. Literature data show [10] that DBS electrodes can be used for

radiofrequency (RF) lesions. The lesions could be safely staged and adapted to the symptoms with encouraging results [11]. We report a case of generalized primary dystonia treated with RF lesioning of the Gpi by means of an electrode previously used for DBS.

Material and Methods

Experimental Data on DBS Electrode Used to Make RF Lesioning

In our institute preliminary experiments were performed on egg white to calculate the relationship between RF parameters applied through a quadripolar DBS lead (3387; Medtronic, Minneapolis, Minn., USA) and the size of the lesion. Different voltages (10–50 V) and different lengths of lesioning (10–60 s) were applied between two adjacent electrodes of the DBS lead inserted into egg whites. The size of the coagulum increased gradually with voltage up to a plateau observed after 30 s from the lesioning onset. The mean size of the coagulum increased gradually with voltages from 20 to 50 V. Thirty RF lesions were performed at 40 V; the mean size of the length of the coagulum was 4 mm (range 2.9–5 mm), and the mean size of the width was 2.2 mm (range 1.5–3.4 mm).

Case Report

The patient is a 14-year-old boy who began to complain of gait difficulties for a dystonic posturing of the right foot at the age of 6 years. At the age of 8 years, after a febrile illness, he developed a generalized dystonia with oromandibular involvement, fixed dystonic postures of the trunk and feet, and superimposed continuous dystonic movements especially involving the lower limbs. After extensive investigation the diagnosis of primary DYT1 negative dystonia was made. Brain magnetic resonance imaging (MRI) was normal. Treatment with an anticholinergic agent allowed amelioration of dystonia, and the child was able to walk autonomously, but these benefits were only transient. At the age of 9 years, the neurological conditions worsened severely, leaving the child wheelchair bound and presenting frequent dystonic spasms unresponsive to boluses of diazepam. Due to the severity of the dystonia and the unresponsiveness to medical treatment, in May 2006 (at the age of 11 years) the child was readmitted to our hospital for the surgical intervention of bilateral DBS of the Gpi.

The pre-operative total score at the Burke-Fahn and Marsden Dystonia rating scale (BFMDRS) was 116.5 (the disability score was 25 and the severity score 91.5). The treatment was well tolerated and the postoperative period was uneventful. Symmetric unipolar stimulation was started and the parameters were progressively adjusted according to the clinical response. Two years after surgery (April 2008), the total BFMDRS score was 75 (the disability score was 15 and the severity score 60) and stimulation parameters were 4.5 V, 120 μ s and 185 Hz.

In August 2008, the stimulation device on the right side became infected (skin erosion of the head, along the path of the connector); the operation of right pallidotomy by the DBS electrode and the removal of the whole right DBS system were then planned.

Pallidotomy by Using DBS. In August 2008, pallidotomy by the DBS electrode was performed under general anaesthesia. The left

pulse generator was powered off, and the right electrode was isolated and connected by a custom-made cable to the RF generator Cosman RFG-1A (Cosman Medical Inc., Burlington, Mass., USA). Based on the best clinical response achieved, before infection onset, by unipolar stimulation with contacts 1, 2 and 3 active (-), 2 bipolar RF lesions were performed as follows: lesion 1, contact 1(+) and contact 2(-), 40 V for 30 s; lesion 2, contact 3(+) and contact 2(-), 40 V for 30 s. An impedance of 1,000 Ω was recorded in both sessions. At the end of surgery the right electrode was easily removed, and the early postoperative CT excluded right Gpi complications including bleeding.

Brain MRI was performed 2 months after lesioning according to the guidelines of the DBS producer (Medtronic; 1.5 T with horizontal magnet; specific absorption rate of 0.1 W/kg; gradient dB/dt field of 20 T/s, pulse generator off and voltage 0).

Electron Microscopy Study. Scanning electron microscopy (SEM) was performed with Jeol JSM 84, equipped with a magnetic field cancelling system (Magnetic Field Cancelling System, SC20, Spicer Consulting). The images were acquired at 5 kV at low magnifications. The contact features of the electrode, used for RF lesions (3389; Medtronic), were analysed and matched with the 4 contacts of a DBS electrode not used for RF lesions (3387; Medtronic).

Results

Early postoperative complications including bleeding were not observed. After the right pallidotomy, a long-lasting stable control of dystonia was observed, and 9 months from lesioning procedure, with the left DBS electrode still active, the BFMDRS was the same as that recorded with bilateral stimulation (total score 75; disability score 15, severity score 60). The left Gpi was still under stimulation with the following parameters: 4.5 V, 120 μ s and 185 Hz.

The MRI performed 2 months from lesioning (fig. 1) showed a small area covering the right posterolateral Gpi characterized by a T₁- and T₂-weighted hyperintensity signal corresponding to the electrode contacts used for lesions.

The SEM scans of the DBS electrode used for RF lesioning showed no alteration of the ultrastructure at different magnifications ($\times 40$ and $\times 300$). In contacts 3 and 2, the SEM scan showed the presence of a clot related to the RF lesion; it was bigger in contact 2 (used for the 2 consecutive RF stages; fig. 2).

Discussion

DBS is an effective and reversible procedure but introduces hardware-related complications not observed after RF lesions [10, 12]. Literature data showed [13] that DBS

electrodes could be used for RF lesions, safely staged and adapted to the symptoms [14]. Oh et al. [13] reported 2 cases that had undergone DBS implantation for essential tremor and PD, respectively, and assessed the relationship between RF parameters and lesion size in vitro. In this report several variables were observed that influenced the coagulum size and shape including the impedance of the system, and damage of the DBS lead used for repeated lesioning. The lesion features are related to the RF current, with the highest current the most reproducible for the size and shape of the lesion. In both patients the electrode was not removed, and 6 months after a single RF lesion long-lasting results were observed [13]. In vitro lesions (i.e. using egg whites) are generally considered as a suitable model for studying lesions produced by RF. Our preliminary results were similar to those previously reported, and there was no evidence of macroscopic damage to the DBS electrodes, although used 5–10 times for experimental RF lesions (fig. 3).

A more recent study based on the use of a DBS electrode for RF lesions demonstrated the possibility to obtain lesions with a mean length of 5 mm at 40 V in egg white and brain cadavers [15]. The same study reported the possibility of repeating a large number of procedures without damage to the electrode. Consequently we decided to use a DBS electrode for RF lesions. According to previous experience we report for the first time in the literature a successful procedure on a paediatric case in which the electrode was removed soon after the RF lesioning. The impedance recorded during the procedure was 1,000 Ω and after 2 stages of 40 V for 30 s, the size of each lesion, observed in postoperative MRI, was in accordance with that planned (fig. 1).

The patient is still under left continuous high-frequency stimulation, and 9 months after the right Gpi RF lesion the control of dystonic symptoms is stable. The control of symptoms is related to the left stimulation and to the right RF lesion. This result is in accordance with a previous experience observed in the same patient in whom 18 months after bilateral DBS surgery a new onset of severe dystonia appeared after the expiration of the right pulse generator (Solettra, Medtronic). The efficacy of the combination of high-frequency stimulation and RF lesioning is reported [16, 17].

DBS has become the standard of care for appropriate drug-refractory syndromes previously treated by RF lesioning; there remain situations where lesion therapy provides a reasonable alternative. Hooper et al. [14] retrospectively analysed a large series of patients and suggested several conditions that in the DBS era are still eli-

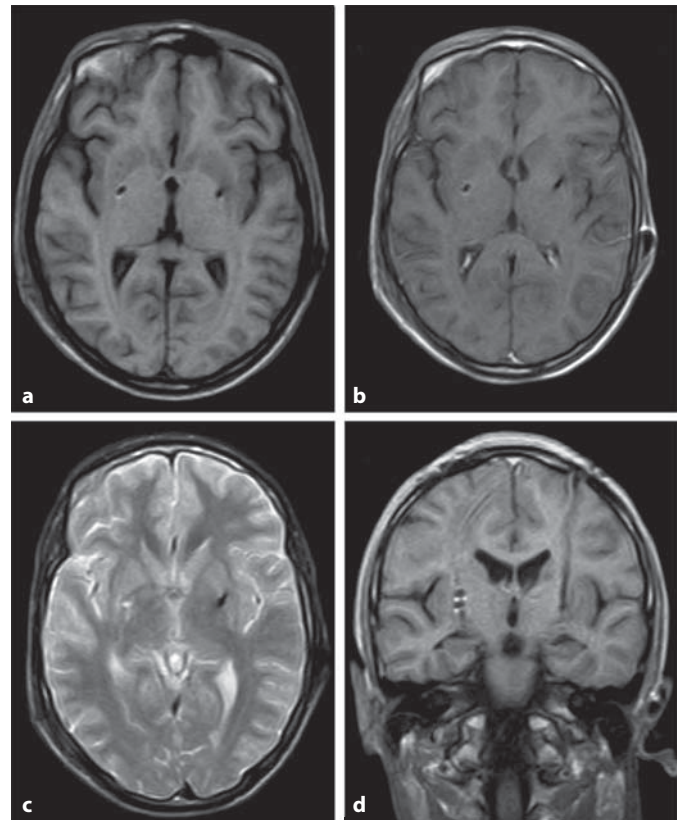


Fig. 1. MRI performed 2 months from RF lesioning. The MR image shows a small area in the right Gpi with a T₁-weighted hyperintensity signal corresponding to the electrode contacts 1, 2 and 3 used for the RF lesions. **a** Axial T₁-weighted image. **b** Axial T₁-weighted image with gadolinium. **c** Axial T₂-weighted image. **d** Coronal T₁-weighted image with gadolinium.

gible for lesioning including immunocompromised patients, patients who cannot have a frequent follow-up, patients who could develop skin erosion (elderly subjects and children younger than 8 years) and patients to be submitted to a unilateral procedure.

The Nantes group reported an interesting clinical experience based on 3 patients in whom the RF lesion by DBS electrode was planned ab initio. The rationale of the study was based on the possibility to leave the electrode implanted, to verify the correct placement of the electrode and to obtain clinical results with small lesions without side effects. The study design considered the increase in the lesion size at symptom recurrence. The authors concluded that the safety, the efficacy, the possibility of performing many RF lesions, the far lower cost than that of DBS and the small number of outpatient visits made this procedure very attractive [18].




Fig. 2. SEM micrographs of electrode contact. Bar: $\times 44 = 200 \mu\text{m}$, $\times 300 = 50 \mu\text{m}$. **a** Contact 0 of the lesioning electrode (Medtronic 3389) not used for the RF lesion at $\times 44$. **b** Same contact at $\times 300$. **c** Contact 2 of the lesioning electrode used in both RF lesion stages: a large surface is wrapped by the coagulated brain tissue ($\times 44$). **d** The same clot visualized at $\times 300$.

Our results showed that coagulum size gradually increases within 30 s of the lesioning onset. Within the same time frame, the best size and shape of the lesion were observed at 40 V. The SEM analysis of the electrode excluded damage to the DBS electrode contacts and also demonstrated an increasing amount of coagulated tissue related to the numbers of RF stages. This feature does not seem to be related to the safety of electrode removal soon after the first stages of RF lesions; the adhesion of the coagulated brain tissue to the electrode contacts should be considered an additional risk factor for bleeding in cases of delayed removal of the DBS electrode.

In our opinion, this procedure has to be considered for patients in whom thinness and severity of symptoms increase the chance of infection or erosion. Children affected by severe dystonia could benefit from this procedure, particularly those affected by status dystonicus, which by lesioning alone or combined with DBS in different targets (Gpi or nucleus subthalamicus [pers. experience]) could control dystonic symptoms. Staged RF le-

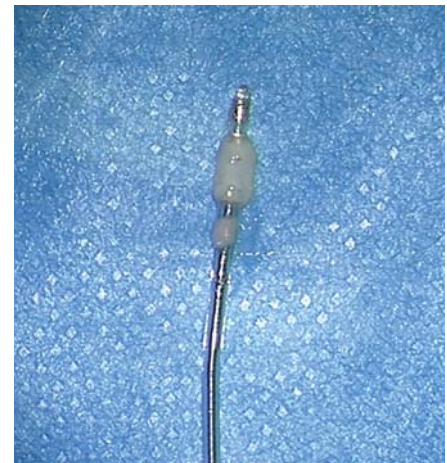

Fig. 3. Photograph of coagulum in egg whites mimicking the lesion performed in our case with the following contacts: 1(+) and 2(-) in the first session, and 3(+) and 2(-) in the second at 40 V for 30 s for each stage.

sioning could also be indicated for patients with a short life expectancy affected by cancer pain and for aged patients (over 70) with unilateral tremor in whom staged lesions of the ventral intermediate nucleus allow better long-term control of tremor than a single lesion. We believe that the lesion technique using a DBS electrode allows small and staged lesions and could also be performed when the target is bilateral. On the other hand, it is not recommended in patients with a higher risk of hardware-

related complications. The versatility, efficacy, safety and low cost of the electrode also make this approach suitable in developing countries.

Acknowledgement

We thank Davide Marchesi of the Department of Physics, University of Milan, for his technical support and Marco Merlin for logistic contribution.

References

- 1 Fahn S: Concept and classification of dystonia. *Adv Neurol* 1988;50:1–8.
- 2 Fahn S, Bressman SB, Marsden CD: Classification of dystonia. *Adv Neurol* 1998;78:1–9.
- 3 Jankovic J: Medical therapy and botulinum toxic in dystonia. *Adv Neurol* 1998;78:169–183.
- 4 Coubes P, Roubertie A, Vayssiere N, et al: Treatment of DYT1-generalised dystonia by stimulation of the internal globus pallidus. *Lancet* 2000;355:2220–2221.
- 5 Zorzi G, Marras C, Nardocci N, Franzini A, Chiapparini L, Maccagnano E, Angelini L, Caldiroli D, Broggi G: Stimulation of the globus pallidus internus for childhood-onset dystonia. *Mov Disord* 2005;20:1194–1200.
- 6 Hung SW, Hamani C, Lozano AM, Poon YY, Piboolnurak P, Miyasaki JM, Lang AE, Dostrovsky JO, Hutchison WD, Moro E: Long-term outcome of bilateral deep brain stimulation for primary cervical dystonia. *Neurology* 2007;68:457–459.
- 7 Vidailhet M, Vercueil L, Houeto JL, Krystkowiak P, Lagrange C, Yelnik J, Bardinet E, Benabid AL, Navarro S, Dormont D, Grand S, Blond S, Ardouin C, Pillon B, Dujardin K, Hahn-Barma V, Agid Y, Destée A, Pollak P: French SPIDY Study Group: Bilateral, pallidal, deep brain stimulation in primary generalised dystonia: a prospective 3 year follow-up study. *Lancet Neurol* 2007;3:223–229.
- 8 Franzini A, Marras C, Ferroli P, Zorzi G, Bugiani O, Romito L, Broggi G: Long-term high-frequency bilateral pallidal stimulation for neuroleptic-induced tardive dystonia: report of two cases. *J Neurosurg* 2005;102:721–725.
- 9 Blomstedt P, Harzi MI: Hardware related complications of deep brain stimulation: a ten year experience. *Acta Neurochir* 2005;147:1061–1064, discussion 1064.
- 10 Oh MY, Abosch A, Kim SH, Lang AE, Lozano AM: Long-term hardware-related complications of deep brain stimulation. *Neurosurgery* 2002;50:1268–1276.
- 11 Su PC, Tseng HM, Liou HH: Postural asymmetries following unilateral subthalamotomy for advanced Parkinson's disease. *Mov Disord* 2002;17:191–194.
- 12 Patel NK, Heywood P, O'Sullivan K, McCarter, Love S, Gill SS: Unilateral subthalamotomy in the treatment of Parkinson's disease. *Brain* 2003;126:1136–1145.
- 13 Oh MY, Hodaie M, Kim SH, Alkhani A, Lang AE, Lozano AM: Deep brain stimulator electrodes used for lesioning: proof of principle. *Neurosurgery* 2001;49:363–369.
- 14 Hooper AK, Okun MS, Foote KD, Fernandez HH, Jacobson C, Zeilman P, Romrell J, Rodriguez RL: Clinical cases where lesion therapy was chosen over deep brain stimulation. *Stereotact Funct Neurosurg* 2008;86:147–152.
- 15 Raoul S, Leduc D, Vegas T, Sauleau P, Lozano A, Verin M, Damier P, Lajat Y: Deep brain stimulation electrodes used for staged lesion within the basal ganglia: experimental studies for parameter validation. *J Neurosurg* 2007;107:1027–1035.
- 16 Cersosimo MG, Raina GB, Piedimonte F, Antico J, Graff P, Micheli FE: Pallidal surgery for the treatment of primary generalized dystonia: long-term follow-up. *Clin Neurol Neurosurg* 2008;110:145–150.
- 17 Eriksson O, Wardell K, Bylund NE, Kullberg G, Rehncrona S: In vitro evaluation of brain lesioning electrodes (Leskell) using a computer-assisted video system. *Neurol Res* 1999;21:89–95.
- 18 Raoul S, Faighel M, Rivier I, Verin M, Lajat Y, Damier P: Staged lesions through implanted deep brain stimulating electrodes: a new surgical procedure for treating tremor or dyskinesias. *Mov Disord* 2003;18:933–937.