

# Intracranial spontaneous hypotension associated with CSF cervical leakage successfully treated by lumbar epidural blood patch

Angelo Franzini · Edvin Zekaj · Giuseppe Messina ·  
Eliana Mea · Giovanni Broggi

Received: 9 August 2010 / Accepted: 17 August 2010  
© Springer-Verlag 2010

Dear Editor,

Intracranial hypotension syndrome (IHS) typically presents with postural headache, often associated with one or more of the following symptoms: nausea, vomiting, dizziness, diplopia, photophobia, hearing impairment, neck stiffness, and blurred vision [1].

This condition is secondary to reduction of cerebrospinal fluid (CSF) volume. Most patients with spontaneous IHS have a CSF leak in the spinal dural sac demonstrated by myelographic magnetic resonance (MR) or by isotopic myelography. Some authors have hypothesized that the main causative factor of IHS could be the unbalance between negative spinal epidural pressure and CSF pressure [2].

Magnetic resonance imaging (MRI) of the brain with contrast enhancement is the imaging study of choice for patients suspected of IHS [3]. Characteristic radiologic abnormalities include diffuse thickening of the pachymeninges, contrast enhancement of the pachymeninges, subdural fluid collections or subdural hematomas that are frequently bilateral, and downward displacement of the brainstem and cerebellar tonsils [3, 4]. Computed tomography myelography, spinal MRI, and radionuclide cisternography are the imaging studies used frequently for the localization of the CSF leak site [3, 5].

Treatment of spontaneous IHS begins with bed rest and intravenous fluid administration to restore the depleted CSF volume [3]. Pharmacological therapy includes intravenous or oral caffeine, theophylline, and steroids. In cases refractory to conservative therapy, epidural blood patch (EBP) and/or surgical repair are indicated [6, 7].

We report a patient affected by IHS whose myelo-MRI disclosed cervical CSF leakage and who was successfully treated with spinal lumbar blood patch.

This patient presented persistent headache associated with photophobia and hyperpyrexia. In the suspect of meningitis, he underwent a lumbar puncture; the cytochemical exam revealed only mild proteins' increase. He performed a brain MRI with gadolinium enhancement which evidenced a linear, diffuse pachymeningeal thickening with evident enhancement (upper left in Fig. 1). The maximum intensity projection reconstructions and myelographic effect showed probable points of liquorale leakage bilaterally at C1–C2 level and on the right side of C2–C3 level (lower left in Fig. 1). On the lumbar spine, the dural sac appeared collapsed. Before considering direct repair of the fistula or cervical blood patch, following our hypothesis [2], we performed a L2–L3 “focal” epidural blood patch by injecting 5 ml of fibrin glue mixed with 5 ml of autologous blood and 3 ml of hydrosoluble contrast medium. After the procedure, the patient had a remission of the symptomatology. Brain MRI performed 1 week later showed a reduction of the pachymeningeal thickening.

Brain MRI was repeated after 2 months and revealed an evident reduction of dural contrast enhancement (upper right in Fig. 1). Two years after the procedure, the patient is still free of symptoms, and MRI is normal.

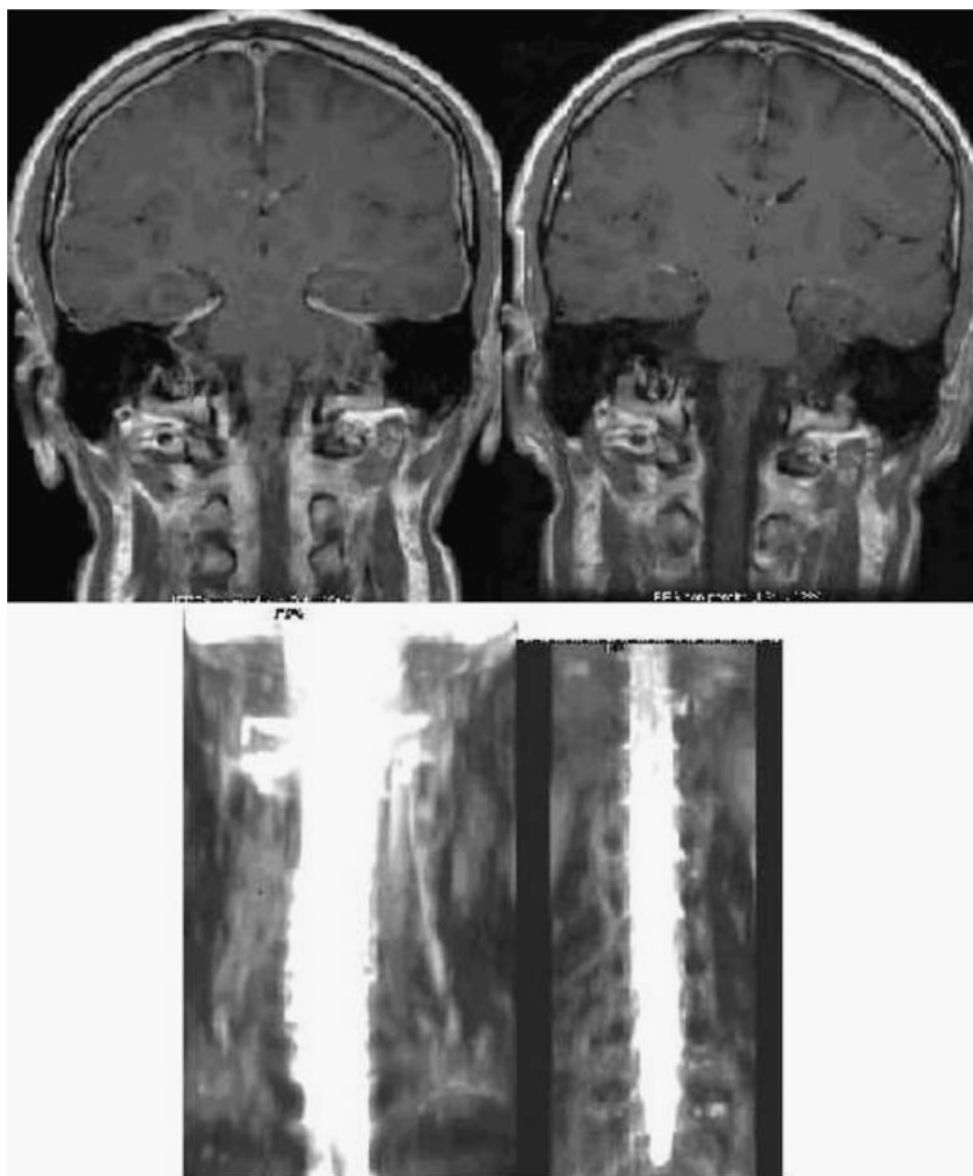
The injection site of epidural blood patch has not yet been standardized. Some authors believe that the EBP should be performed at the same spinal level of a CSF leak

---

A. Franzini · E. Zekaj · G. Messina (✉) · G. Broggi  
Department of Neurosurgery, Fondazione IRCCS Istituto  
Nazionale Neurologico “Carlo Besta”,  
Via Celoria 11,  
20133 Milan, Italy  
e-mail: giusmex@gmail.com

E. Mea  
Department of Neurology, Fondazione IRCCS Istituto Nazionale  
Neurologico “Carlo Besta”,  
Milan, Italy

**Fig. 1** *Upper left*—coronal T1-sequences after gadolinium shows a diffuse meningeal enhancement. *Upper right*—2 months after the procedure, the dural enhancement is greatly reduced. *Lower left*—a myelo-MRI which evidences the site of CSF leakage localized at C1–C2 and C2–C3 on the right side. *Lower right*—the myelo-MRI of thoracic and lumbar spine did not reveal any other leakage site



[8]. Rai et al. have performed a cervical blood patch after two failed attempts of lumbar epidural blood patch [9]. The authors ascribed the failure of lumbar blood patch to the large size of the CSF leakage point. Several authors advocated the usage of a “blind” EBP with a uniform injection site in the lumbar spine, without identifying the actual site or CSF leakage’s level with spinal imaging studies [10]. The patient’s head is lowered to 30°, immediately after the injection so that the epidural blood spreads into the cephalad direction.

We believe that IHS is a complex syndrome secondary to persistent reduction of CSF volume which is sustained by a chronic overdrainage of CSF, and that the basis of excessive liquor loss is not sustained by a “hole” in the dura mater, but

(as previously reported) it may be secondary to a more complex mechanism of CSF aspiration by spinal epidural veins [2]. Our procedure is aimed to collapse lumbar epidural veins, thus leading to a stable rise in epidural pressure due to the disconnection of the low-pressure epidural lumbar venous network supplied by the inferior vena cava vein from the epidural thoracic and cervical venous network supplied by the superior vena cava vein. This is obtained with “dense” and “focal” epidural blood patch performed in the lumbar spine, thus avoiding unnecessary risks of an eventual cervical epidural blood patch.

**Conflicts of interest** None.

## References

1. Mokri B (2003) Headaches caused by decreased intracranial pressure: diagnosis and management. *Curr Opin Neurol* 16:319–326
2. Franzini A, Messina G, Nazzi V, Mea E, Leone M, Chiapparini L, Broggi G, Bussone G (2010) Spontaneous intracranial hypotension syndrome: a novel speculative physiopathological hypothesis and a novel patch method in a series of 28 consecutive patients. *J Neurosurg* 112:300–306
3. Paldino M, Mogilner AY, Tenner MS (2003) Intracranial hypotension syndrome: a comprehensive review. *Neurosurg Focus*; 15(6): ECP2
4. Chiapparini L, Ciceri E, Nappini S, Castellani MR, Mea E, Bussone G, Leone M, Savoiaro M (2004) Headache and intracranial hypotension: neuroradiological findings. *Neurol Sci* 25(Suppl 3):S138–S141
5. Chiapparini L, Farina L, D'Incerti L, Erbetta A, Pareyson D, Carriero M R, Savoiaro M (2002) Spinal radiological findings in nine patients with spontaneous intracranial hypotension. *Neuroradiology* 44(2):143–150, discussion 151–2
6. Berroir S, Loisel B, Ducros A, Boukobza M, Tzourio C, Valade D, Bousser MG (2004) Early epidural blood patch in spontaneous intracranial hypotension. *Neurology* 63(10):1950–1951
7. Sencakova D, Mokri B, McClelland RL (2001) The efficacy of epidural blood patch in spontaneous CSF leaks. *Neurology* 57:1921–1923
8. Dillo W, Hollenhorst J, Brassel F, von Hof-Strobach K, Heidenreich F, Johannes S (2002) Successful treatment of a spontaneous cervical cerebrospinal fluid leak with a CT guided epidural blood patch. *J Neurol* 249:224–225
9. Rai A, Rosen C, Carpenter J, Miele V (2005) Epidural blood patch at C2: diagnosis and treatment of spontaneous intracranial hypotension. *AJNR Am J Neuroradiol* 26(10):2663–2666
10. Cohen A, Jesuthasan M (2004) 'Blind' epidural blood patch for spontaneous intracranial hypotension. *Anaesthesia* 59:190–191