

## Staged pallidotomy: MRI and clinical follow-up in status dystonicus

Angelo Franzini, Vincenzo Levi, Andrea Franzini, Ivano Dones & Giuseppe Messina

To cite this article: Angelo Franzini, Vincenzo Levi, Andrea Franzini, Ivano Dones & Giuseppe Messina (2017): Staged pallidotomy: MRI and clinical follow-up in status dystonicus, British Journal of Neurosurgery, DOI: [10.1080/02688697.2017.1409875](https://doi.org/10.1080/02688697.2017.1409875)

To link to this article: <https://doi.org/10.1080/02688697.2017.1409875>



Published online: 28 Nov 2017.



Submit your article to this journal [↗](#)



View related articles [↗](#)



View Crossmark data [↗](#)

## Staged pallidotomy: MRI and clinical follow-up in status dystonicus

Angelo Franzini, Vincenzo Levi, Andrea Franzini, Ivano Dones and Giuseppe Messina

Functional Neurosurgery Unit, Fondazione IRCCS Istituto Neurologico Carlo Besta, Milan, Italy

### ABSTRACT

**Purpose:** We report on a patient affected by Status Dystonicus who was treated with Deep Brain Stimulation electrodes implanted in the Globus Pallidus internus (Gpi) and used for serial radiofrequency lesions.

**Materials and Methods:** The evolution of radiofrequency lesions was monitored by post-operative and late Magnetic Resonance Imaging (MRI). After the first lesion the patient did improve, though not in a significant fashion. Therefore, three further radiofrequency lesions were delivered 2, 4 and 6 days respectively after surgery with subsequent improvement of dystonic movements.

**Results:** MRI scans performed at 8 days, 3 months, and 6 months after surgery showed a diffuse T2-hyperintense and T1-hypointense GPi signal alteration which progressively decreased over time.

**Conclusion:** We confirm that the possibility to stage pallidotomies over time using a couple of new contacts is a safe and efficacious procedure in treating SD patients where the lesions themselves are limited by the appearance of side effects, or in patients showing a poor response to a single lesion. As far as we know, this is the first description of MRI evolution and monitoring of a staged pallidotomy.

### ARTICLE HISTORY

Received 22 February 2017  
Revised 22 September 2017  
Accepted 21 November 2017

### KEYWORDS

Staged pallidotomy; status dystonicus; generalized dystonia; globus pallidus internus

### Introduction

Dystonia is a movement disorder characterized by sustained or intermittent muscle contractions causing abnormal, often repetitive movements, postures or both.<sup>1</sup>

A minority of patients with dystonia may present, in the context of a worsening picture of such disease, a condition characterized by severe and generalized dystonic spasms often refractory to standard pharmacological treatment. This condition is termed status dystonicus (SD) or “dystonic storm”. This is a rare and heterogeneous condition, with a male predominance. In addition, 60% of these cases are between 5 and 16 years of age.<sup>2</sup> The real incidence of this disease is not precisely known, because of the relative paucity of reported cases in international literature, and, as such, it could be higher than expected. SD is considered to be a life threatening pathology because the spasms, that are extremely painful, often interfere with respiratory and neurovegetative functions, thus causing metabolic imbalances such as hyperpyrexia, dehydration, respiratory insufficiency, and acute renal failure secondary to rhabdomyolysis.<sup>3,4</sup> The latter condition is particularly dangerous for the subsequent hyperkalaemia, acidosis, hypocalcaemia and other complications. SD more mostly occurs in the context of acquired (secondary) dystonias and is often precipitated by events such as fever, trauma, surgery and by drugs such as haloperidol, metoclopramide, clonazepam.<sup>5</sup> In a recent series of 5 patients, Deep Brain Stimulation (DBS) was shown to be an effective therapy for such patients,<sup>6</sup> although the reported cases are too few to draw any definitive conclusion on its overall efficacy; anyway, surgical lesional techniques remain a viable option in cases where DBS is not feasible (such as when the risk of complications of DBS are high, or in the case patients or their caregivers do not accept the insertion of an implanted device). Recent reports witness the feasibility and efficacy of

bilateral pallidotomy in patients with status dystonicus or with severe and disabling dystonia.<sup>7</sup>

### Conservative treatment

SD is managed in an Intensive Care Unit (ICU) setting, and often deep sedation and mechanical ventilation become necessary. Several drugs can be employed to prevent or treat SD. Intravenous or enteral clonidine (administered in boluses or in continuous infusion, up to 5 µg/kg/hr when using the enteral route) is useful to reach sedation and has less respiratory-depressant effects; although other drugs have been reported to be useful in preventing SD (such as gabapentin, trihexyphenidyl, amitriptyline, several benzodiazepines and anticonvulsants such as carbamazepine or valproate), often more aggressive measures are necessary. For stronger sedation, continuous intravenous midazolam (30–100 µg/kg/hr) is used for its rapid effect and short half-life; if it is not sufficient, intravenous propofol (0.3–3 mg/kg/hr) together with muscular paralyzing agents and orotracheal intubation become mandatory.

### Surgery

When such procedures prove to be inefficient an invasive approach is recommended. Intrathecal baclofen, tried in a small proportion of these patients, has shown to be only partially effective, and to harbor various serious risks such as withdrawal syndrome and overdose.<sup>8,9,10</sup> Stereotactic thalamotomy,<sup>11</sup> pallidotomy,<sup>2,12</sup> and Deep brain stimulation (DBS) of the Globus Pallidus Internus (GPi)<sup>13,14</sup> have been performed with success in reverting SD.

GPI DBS demonstrates the advantages of being a reversible, modifiable and non-lesional technique. Despite these advantages, it harbors a series of hardware-related problems over lesioning techniques. In these patients, DBS may be complicated by infection, lead fracture or migration, and pulse generator malfunction. Those issues are accentuated in pediatric patients with SD because they have poor skin turgor, minimal subcutaneous tissue, and a suboptimal nutritional status exposing them to recurrent infections. Moreover, being hospitalized in an intensive care unit may increase the risk of infections.

## Case report

The 9-year-old patient was admitted to our institute in March 2016; the clinical picture was characterized by severe generalized dystonia with mental and language impairment. The etiology was unknown and genetic assessment was negative for mutations (idiopathic dystonia), neuro-radiological examinations all being negative. At the age of 5 months, abnormal postures and rapid dystonic movements of trunk, inferior and superior limbs were observed in this child. Subsequently, the dystonic movements extended to the oro-facial segment resulting in dysphagia. Despite pharmacological therapy with L-Dopa, the clinical picture progressively worsened, and infections of the airways through an ab-ingestis mechanism occurred. At the age of 9 years, an episode of pyrexia (until 39°C) triggered the status dystonicus, which was refractory to therapy with phenobarbital, baclofen, trihexypenidyl, quetiapine and midazolam. Aetiology of pyrexia could not be determined despite of several blood, urinary, and bronchial cultures (all negative); no other signs of infection were evident. Creatine Kinase blood levels reached 1500 IU/l

He rapidly developed severe opisthotonus, and generalized involuntary movements (dystonic movements of orbicularis oculi, orbicularis oris, of the head, phasic appendicular movements involving all four limbs. The patient, admitted to the Intensive Care Unit of our hospital, required mechanical ventilation and deep sedation with thiopentone, midazolam, dexmedetomidine and fentanyl. After resolution of the initial pyrexial episode, SD persisted, and he also experienced recurrent upper and lower airway infections and dynamic ileus due to the high dose of anticholinergic drugs administered to control bronchorrhoea and sialorrhoea, thus undergoing tracheostomy.

At that stage, surgical stereotactic therapy was considered. Because of malnutrition and patient's poor skin condition, it was decided to avoid implanting DBS devices, but to perform staged pallidotomy (two weeks) through bilateral GPi implanted electrodes.

Surgery was performed under general anesthesia with the Maranello frame (Maranello, Maranello, Italy). Computerized Tomography (CT) performed in stereotactic conditions was merged with MRI with the aid of Stealth Station (FrameLink, Medtronic Inc.). Intraoperative continuous limbs' electromyography (EMG) was used during the procedure. Two quadripolar DBS leads (3389; Medtronic, Inc., Minneapolis, MN) were implanted in the GPi on both sides. These electrodes consist of four cylindrical contacts (diameter: 1.27 mm, length 1.5 mm, inter-electrode gap 0.5 mm) named 0-1-2-3, beginning from the most caudal contact. The definitive stereotactic coordinates referred to the commissural system midpoint were: 20 mm lateral (X), 4 mm anterior (Y), and 4 mm below the commissural plane (Z). The deep brain electrodes were then tunneled through the galea and connected to an external lead, which constituted an interface to the lesioning system (external radiofrequency

generator (RFG-1A, Cosman Medical Inc., Burlington, MA, USA), used to perform serial pallidotomies.

A bipolar stimulation (with the following electrical parameters: 50 Hz, 100 microseconds, up to 7 Volts) was performed bilaterally between the deepest and the most proximal contact (0-3) and between the two central contacts (1-2) to rule out motor responses due to eventual capsular involvement. A CT scan with the frame still in place was performed after the procedure to check the relationship with the capsular bundle and the optic tract before inflicting the RF lesions.

The first radiofrequency bipolar lesion was performed bilaterally between the central contacts two days after surgery with a 40-seconds' train of 40 volts through the radiofrequency generator. The EMG activity (recorded the same day of the first lesioning session) showed immediate reduction of spontaneous muscle activity in both haemibodies.

The clinical picture, after the first session, had improved, though not in a significant fashion (remission of head and face involuntary movements, but persistence of the limb movements, even if less severe in extent). Our previous experience with a patient affected by generalized dystonia, who underwent serial closer pallidotomies after local field potentials' recording (LFP) with favourable outcome, prompted us to perform further pallidotomies. Three more radiofrequency bipolar lesions were thus delivered with the same parameters respectively 2, 4, and 6 days after surgery. In all cases, we decided to use the central contacts (1 and 2) bilaterally for lesioning. Eight days after surgery MRI was performed and showed a diffuse Gpi T2-hyperintense signal alteration on both sides (Figure 1)

SD gradually improved in the following days (significant improvement also of the limbs' dystonia, partial control of the head and neck) Thiopentone administration was no longer necessary (its administration had lasted for 15 days from the onset of SD), and the dosage of midazolam in continuous infusion was progressively reduced until withdrawal; oral feeding was again possible and the electrodes were then removed.

Two months after surgery the little patient showed only mild appendicular dystonic movements and slight oromandibular dystonia triggered by pain or discomfort. He also presented mild generalized hypotonia and partially regained finalized movements of the limbs, such as an independent respiratory function. Tracheostomy was removed. Consciousness was re-established, as well as the ability to answer simple questions.

MRI scans performed 3 and 6 months after surgery showed reduction of the diffuse Gpi lesions, with persistence of circular signal alterations previously surrounding the electrodes. (Figure 1)

## Discussion and conclusion

Surgery is required for those patients with SD who do not experience significant improvement from conservative treatment. Ondo et al in 1998 described the outcome of 8 patients affected by generalized dystonia submitted to unilateral or bilateral pallidotomy (based on side-prevalence of severity of symptoms);<sup>15</sup> in this case, 7 patients showed a significant and sustained clinical benefit whereas one patient showed a 'mild and partial recurrence'; the same patient in this report experienced transient post-operative lethargy. The Authors noticed that the clinical improvement was progressive and not immediate as in Parkinson's disease, thus hypothesizing a role for physiological compensation or neuroplasticity. Marras *et al.* have reported on the efficacy and feasibility of lesional procedures on Gpi in these cases<sup>7,13</sup>. Ben-Haim *et al.*, in

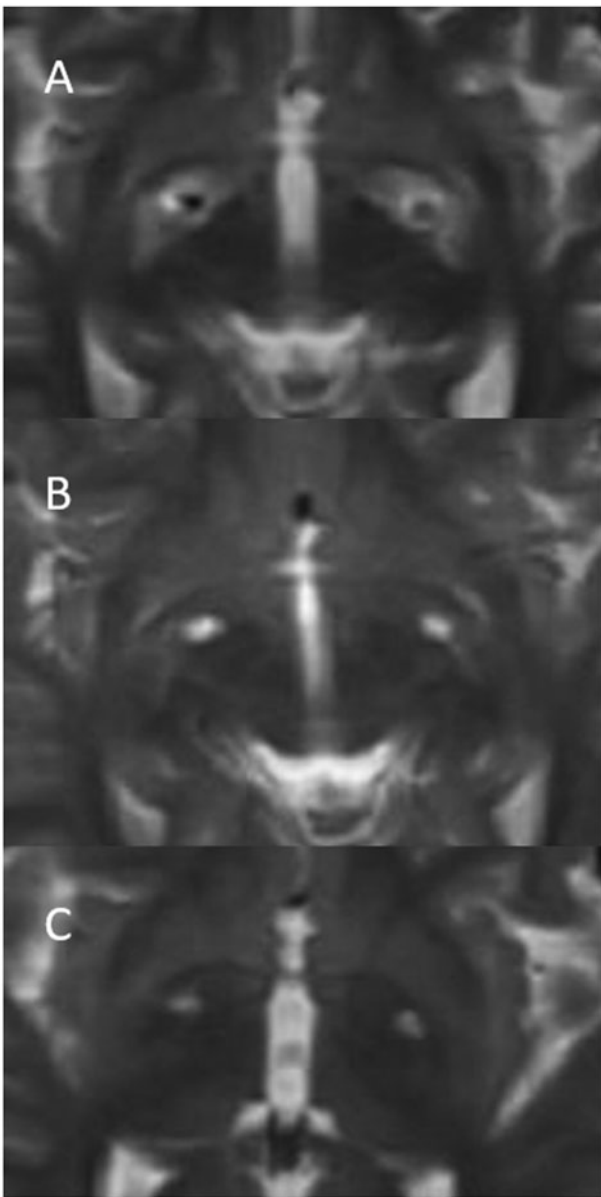


Figure 1. A: MRI scan performed eight days after DBS surgery, with electrodes still in place within the GPi; B and C: MRI scans performed at 3 and 6 months after surgery, respectively.

their recent review, reported a favourable outcome of DBS in 26 out of 28 patients with SD.<sup>6</sup>

Safety and efficacy of pallidotomy has been shown to be similar to those of DBS already by Gross,<sup>14</sup> who underlined that the results with bilateral Gpi DBS were in the same range as those shown after bilateral pallidotomies; drug-refractory SD must be considered a life-threatening condition requiring surgery, and when patients cannot bear DBS components (due to high risk of infection or to poor skin trophism), pallidotomy has to be taken into account, in that it could interrupt a pathological unregulated cortico-basal circuit characterized by decreased intrinsic cortical or thalamic inhibition.<sup>16</sup>

As reported by Ondo,<sup>15</sup> results could not be immediate after a single lesion, but the possibility to perform staged pallidotomies over time is advantageous in SD patients showing a poor response to a single session. We hypothesize that this supposed 'plasticity-driven' process could be accelerated by

repeated lesions. This report shows that being able to repeat the lesions could be a safe and efficacious procedure for treating SD.

Our group, in accordance with Raoul *et al.*<sup>13,17</sup> demonstrated the lack of structural alterations on DBS electrodes after lesioning sessions through Scanning Electron Microscopy (SEM). Furthermore, these two studies showed that the size of the lesions increased with voltage, reaching a plateau after 30 seconds from the onset of the lesion.

Oh *et al.*<sup>18</sup> reported the feasibility and efficacy of performing lesions through DBS electrodes in two patients affected by essential tremor (thalamotomy) and by Parkinson's Disease (sub-thalamotomy), respectively.

This is the first report of a long-term MRI follow-up of a SD patient treated with staged pallidotomy. In this case, the MRI scan performed 8 days after surgery showed a diffuse signal alteration within the whole GPi, and, after 3 and 6 months, a more limited signal alteration extending for about 4 millimeters around the site of previously positioned electrodes. The clinical picture dramatically improved two months after surgery and was maintained at the last clinical follow-up (6 months), despite the neuro-radiological reduction in the size of the lesions. It is thus suggested that, in the initial MRI picture, GPi edema contributed to the extension of the signal alteration, and that the 4 mm lesion size, in the following months, was sufficient to sustain the improvement of the clinical picture.

We recommend this procedure in patients with poor skin trophism, not suitable for DBS or, in general, with general contraindications to permanent intracerebral or subcutaneous devices.

In conclusion, we would like to stress two points. First, the safety of the procedure due to the control of definitive electrode positioning before delivering the RF pallidotomy, which may result in irreversible lesions very close to the optic tract and motor bundle within the internal capsule.

Secondly, the cost effectiveness of using this staged procedure which resulted in about 1600 euros (the cost of the DBS electrodes) versus 16,000 euros (the cost of the full DBS implant including cable and implantable pulse generator).

## Disclosure statement

No potential conflict of interest was reported by the authors.

## References

1. Sanger TD, Chen D, Fehlings DL, *et al.* Definition and classification of hyperkinetic movements in childhood. *Mov Disord* 2010;25:1538–49.
2. Fasano A, Ricciardi L, Bentivoglio AR, *et al.* Status dystonicus: predictors of outcome and progression patterns of underlying disease. *Mov Disord* 2012;27:783–8.
3. Jankovic J, Penn AS. Severe dystonia and myoglobinuria. *Neurology* 1982;32:1195–7.
4. Mariotti P, Fasano A, Contarino MF, *et al.* Management of status dystonicus: our experience and review of the literature. *Mov Disord* 2007;22:963–8.
5. Allen NM, Lin JP, Lynch T, King MD. Status dystonicus: a practice guide. *Dev Med Child Neurol* 2014;56:105–12.
6. Ben-Haim S, Flatow V, Cheung T, Cho C, Tagliati M, Alterman RL. Deep brain stimulation for status dystonicus: a case series and review of the literature. *Stereotact Funct Neurosurg* 2016;94:207–15.
7. Marras CE, Rizzi M, Cantonetti L, *et al.* Pallidotomy for medically refractory status dystonicus in childhood. *Dev Med Child Neurol* 2014;56:649–56.
8. Coffey RJ, Edgar TS, Francisco GE, Graziani V, Meythaler JM, Ridgely PM. Abrupt withdrawal from intrathecal baclofen: recognition and management of a potentially life-threatening syndrome. *Arch Phys Med Rehabil* 2002;83:735–41.

9. Kyriagis M, Grattan-Smith P, Scheinberg A, Teo C, Nakaji N, Waugh M. Status dystonicus and Hallervorden-Spatz disease: treatment with intrathecal baclofen and pallidotomy. *J Paediatr Child Health* 2004;40:322–5.
10. Muirhead W, Jalloh I, Vloberghs M. Status dystonicus resembling the intrathecal baclofen withdrawal syndrome: a case report and review of the literature. *J Med Case Rep* 2010;4:294.
11. Sobstyl MR, Sławek JW, Ząbek M. The neurosurgical treatment of patients in dystonic state - overview of the literature. *Neurol Neurochir Pol* 2014;48:63–70.
12. Manji H, Howard RS, Miller DH, *et al.* Status dystonicus: the syndrome and its management. *Brain* 1998;121:243–52.
13. Marras C, Zorzi G, Lenardi C, *et al.* Deep brain stimulation electrode used for radiofrequency lesion of the globus pallidus internus in dystonia. *Stereotact Funct Neurosurg* 2009;87:348–52.
14. Gross RE. What happened to posteroventral pallidotomy for Parkinson's disease and dystonia? *Neurotherapeutics* 2008;5:281–93.
15. Ondo WG, Desaloms JM, Jankovic J, Grossman RG. Pallidotomy for generalized dystonia. *Mov Disord* 1998;13:693–8.
16. Vitek JL, Delong MR, Starr PA, Hariz MI, Metman LV. Intraoperative neurophysiology in DBS for dystonia. *Mov Disord* 2011;26(Suppl 1):S31–S6.
17. Raoul S, Leduc D, Vegas T, *et al.* Deep brain stimulation electrodes used for staged lesion within the basal ganglia: experimental studies for parameter validation. Laboratory investigation. *J Neurosurg* 2007;107:1027–35.
18. Oh MY, Hodaie M, Kim SH, Alkhani A, Lang AE, Lozano AM. Deep brain stimulator electrodes used for lesioning: proof of principle. *Neurosurgery* 2001;49:363–7.